


PRESENTING CLINICAL SIGNS

History: Coughing/wheezing, BNP 160.

DATE

3/27/23

ECHOCARDIOGRAPHIC FINDINGS

2D, M-mode, and Doppler study.

PERFORMED BY:

Tom McNeill

There is mild left atrial dilation. The mitral valve is normal. Left ventricular wall thickness is normal. Left ventricular internal dimensions are normal. Left ventricular systolic function is hyperdynamic. The aorta and aortic valve are normal. Right atrial and right ventricular dimensions are normal. The tricuspid valve is normal. The pulmonary artery and pulmonic valve are normal. No shunting lesions are visualized. No heartworms are visualized. No pericardial effusion or cardiac masses are seen.

INTERPRETED BY

 Keith Blass, DVM,
 MS, DACVIM
 (Cardiology)

 LA - 17.3 mm
 LA/Ao - 1.68
 IVSd - 4.9 mm
 LVPWd - 4.7 mm
 LVIDd - 15.8 mm
 LVIDs - 6.7 mm
 FS - 57.6%
 RA - 13.4 mm
 LVOT - 0.56 m/s
 RVOT - 0.68 m/s

PATIENT

Spirit McMeeken

SPECIES

Feline

ASSESSMENT/RECOMMENDATIONS

This examination demonstrates mild dilation of Spirit's left atrium, with differentials for this finding including a restrictive cardiomyopathy (RCM), atrial myopathy, and cardiac thyrotoxicosis. Given the presence of mild dilation, it's possible that Spirit's respiratory symptoms could be cardiogenic in origin, should pulmonary edema and/or pleural effusion be present, and thoracic radiographs are recommended for further evaluation. Spirit's risk for cardiac thrombus formation and arrhythmia formation are mildly increased based on this exam, therefore, careful monitoring for these is recommended going forward.

BREED

DSH

SEX

A T4 level is recommended.

FS

I recommend starting Spirit on clopidogrel (18.75 mg SID), as this medication should help to reduce his risk for thrombus formation. Should radiographs indicate the presence of congestive heart failure, additional therapy with furosemide (5 mg BID) and enalapril (1.25 mg BID) would be warranted.

AGE

9 y

Recheck radiographs and a renal/electrolyte profile are recommended in 1 week if furosemide and enalapril are started. A recheck echocardiogram is recommended in 6 months.

WEIGHT

12 lb

HOSPITAL NAME

SVS Imaging CT

REFERRING VET

Dr. Kalirawana



DATE

3/27/23

PERFORMED BY:

Tom McNeill

INTERPRETED BY

Keith Blass, DVM,
MS, DACVIM
(Cardiology)

PATIENT

Spirit McMeeken

SPECIES

Feline

BREED

DSH

SEX

FS

AGE

9 y

WEIGHT

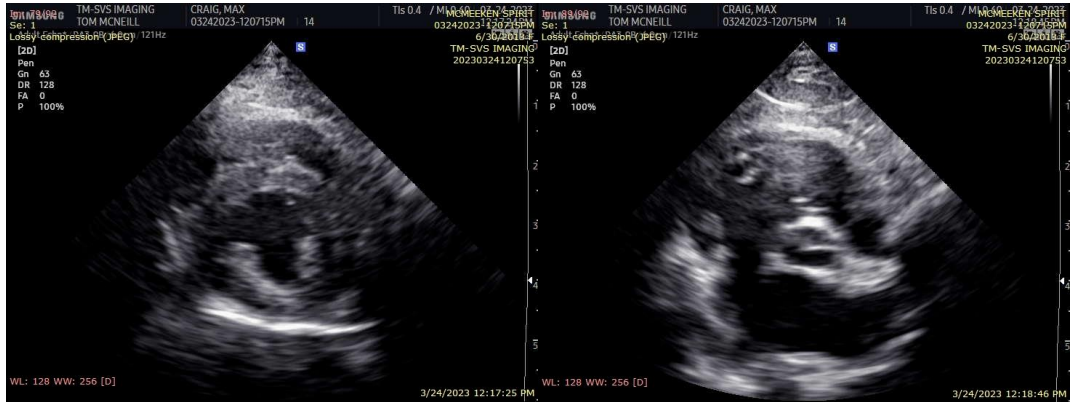
12 lb

HOSPITAL NAME

SVS Imaging CT

REFERRING VET

Dr. Kalirawana



The information and recommendations provided are based on the images presented by the referring veterinarian. No evaluation can be communicated regarding pathology that was not visible in the image/video clips provided.

Thank you for this referral. If the clinical or image interpretation does not parallel your findings or if I can be of any further assistance please contact me.

Keith Blass, DVM, MS, DACVIM (Cardiology)
KeithBlass@gmail.com
631-804-5754